

## SURGERY FOR GRAVES' OPHTHALMOPATHY: WHEN AND WHAT FOR? THE EXPERIENCE OF IASI

V.Costan<sup>1</sup>, R.Costan<sup>2</sup>, C. Bogdanici<sup>3</sup>, L. Moisii<sup>4</sup>,  
E. Popescu<sup>1</sup>, C. Vulpoi<sup>2</sup>, V.Mogos<sup>2</sup>, D. Branisteanu<sup>2,\*</sup>

<sup>1</sup>Department of Maxillo-facial Surgery, <sup>2</sup>Department of Endocrinology,

<sup>3</sup>Department of Ophthalmology, <sup>4</sup>Department of Radiology,

“Gr.T.Popa” University of Medicine and Pharmacy Iasi, Romania

### Abstract

**Introduction.** Orbitopathy is a common extrathyroidal feature of Graves' disease. Initial immune infiltration may be followed by irreversible fibrosis and hypertrophy of extraocular muscles, leading to exophthalmos, diplopia and optic nerve compression. Surgery can improve the quality of life by adapting orbit volume to its content through orbital expansion and/or decompression and through interventions for functional or aesthetical reasons.

**Aim.** To evaluate the impact of orbit surgery on the evolution of Graves' ophthalmopathy.

**Patients and Methods.** Our series includes 21 patients, operated between 2006 and 2012 mainly for proptosis (16 cases) or diplopia (5 cases).

**Results.** Emergency orbit decompression was performed in one patient in the acute phase due to vision loss, reversible after intervention. Orbital extraconal lipectomy was used in all patients, involving both intraconal and extraconal fat in five cases. Unilateral bone decompression was needed in two interventions. 7 patients developed upper

eyelid retraction, treated with botulinum injection in the levator palpebrale. Another patient showed lower lid retraction, elongated with palatal mucosal graft.

**Conclusion.** Adequate surgery should be chosen for each case in an integrated multidisciplinary approach. Both intraorbital fat removal and bone decompression could be concomitantly used in certain patients with severe orbitopathy. Surgery should be performed in stabilized orbitopathy, but emergency intervention might be beneficial in acute onset of vision loss due to optic nerve compression.

**Keywords:** Graves' disease, ophthalmopathy, orbitopathy, surgery, therapy.

### INTRODUCTION

Endocrine orbitopathy (EO) is a chronic autoimmune lesion of the orbit usually associated to thyroid modifications in the context of Graves' disease (1,2). EO is usually bilateral, but may be asymmetric (3). Its

\*Correspondence to: Dumitru Branisteanu MD, PhD, “Gr.T.Popa” University of Medicine and Pharmacy Iasi-Endocrinology, 18 Vasile Conta, Iasi 700106, Romania, Email: dumib@hotmail.com

evolution is unpredictable, with progressive, stabilized and unchanged or spontaneously improving modifications (4).

Lesions involve various orbital structures of which the immune infiltration and enlargement of extraocular muscles, periorbital connective and adipose tissue are most commonly found (3). The expansion of orbital content in a cavity with rigid walls, represented by the bony orbit, leads to compression of the eye globe, frequently accompanied by an increase of the intraorbital pressure (5, 7).

The swelling of extraocular muscles leads to motility impairment that may aggravate and be accompanied by diplopia as disease evolves to an active inflammatory stage (1, 3, 5). The most frequently involved muscles are the rectus inferior and medial, with a limitation of the upward and lateral gaze, but rectus superior and lateral may also be involved (3,5). The initial inflammatory (active) phase usually gets stabilized within one to two years and may even regress (3, 6). Chronic inflammation may however be followed by irreversible fibrosis of extraocular muscles and other structures of the retroorbital space (3, 7). When all extraocular muscles are enlarged and accompanied by retroorbital congestion and infiltration, they may exert a cone of pressure around the orbit apex, constricting the optic nerve and leading to acute decreasing of visual acuity and even vision loss, phenomenon known as the "orbital apex syndrome" (8). Fibrosis may also involve the levator palpebrae and/or the lower lid retractors, causing upper and/or lower lid retraction, respectively, with lack of

coordination between eyelid and eye globe movements (9). These modifications, together with proptosis, lead to incomplete eyelid closure and chronic corneal exposure to trauma and damage (10).

The treatment of Graves' orbitopathy consists in a series of measures in order to maximize the final beneficial result and make it more predictable. Surgical approach of the orbit should be initiated when necessary, if nonsurgical management fails or is followed by incomplete improvement of orbitopathy.

Orbit surgery may improve or even completely reverse all these modifications (11). Proptosis and motility dysfunction are two main ocular modifications corrected by various surgery techniques. They may coexist in the same patient; therefore, surgery has to be adapted individually to the needs of every patient (5-7).

## PATIENTS AND METHOD

Our retrospective experience is based on 21 patients (15 women and 6 men), operated between 2006 and 2012 for Graves' ophthalmopathy (Table 1). Forty-one orbits were submitted to decompression, unilateral intervention being sufficient for one patient. The minimal follow-up period was of 6 months, with periodic evaluations every 6 months. All patients were operated by a single surgeon (Dr. Victor-Vlad Costan) within the Clinic of Oromaxillary Surgery, "St. Spiridon" University Hospital. Surgery was performed only after thyroid function was normalized for

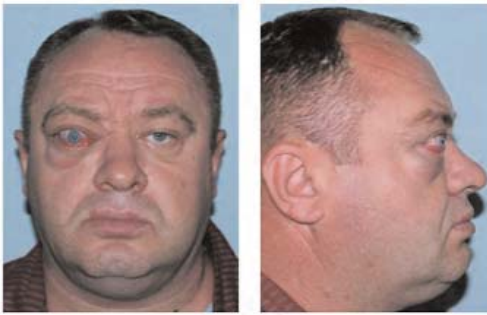Table 1. The 21 patients submitted to orbit surgery. From left to right - age at orbit surgery; smoking status, duration of Graves' orbitopathy before surgery, therapy of hyperthyroidism, total dose of methylprednisolone (MP) used before surgery (g), NOSPECS stadialization of exophthalmos before surgery. Medical therapy of hyperthyroidism was performed either with minimal therapeutic efficient doses of antithyroid drugs (ATD) or with combinations of ATD and levothyroxine (LT4). Radioactive iodine (I131) was given after thyroidectomy in two cases diagnosed with Graves' disease and follicular thyroid carcinoma. GO - Graves' ophthalmopathy. All patients were euthyroid at the moment of surgery. None of the patients was treated by retroorbital irradiation before surgery.

No.	Age	Sex	Smoking	Duration	Therapy	GO medical	NO SPECS
1	42	F	Yes	3 years	ATD, LT4	4.5 g MP	IVA
2	62	F	No	2 years	ATD	4.5 g MP	IIIB
3	65	F	Yes	4 years	thyroidectomy	9 g MP	IIIB
4	58	M	Yes	3 years	ATD	9 g MP	IIIB
5	44	M	Yes	4 years	ATD	13.5 g MP	IVA
6	42	M	Yes	2 years	ATD, LT4	4.5 g MP	IVB
7	27	M	No	2 years	thyroidectomy	9 g MP	IIIB
8	46	F	No	1 year	ATD	0	IIIB
9	60	F	No	3 years	thyroidectomy	4.5 g MP	IVA
10	18	F	No	1 year	thyroidectomy I <sup>131</sup>	3 g MP	IIIB
11	39	F	No	3 years	thyroidectomy	13.5 g MP	IIIB
12	61	F	No	2 years	ATD	4.5 g MP	IVA
13	31	F	Yes	1 year	ATD, LT4	0	IIIB
14	41	F	No	1 year	ATD, LT4	4.5 g MP	IIIB
15	47	M	No	4 years	ATD	13.5 g MP	VIC
16	71	F	No	3 years	ATD	13.5 g MP	IVB
17	31	F	No	3 years	thyroidectomy I <sup>131</sup>	13.5 g MP	IVC
18	29	M	No	2 years	ATD	4.5 g MP	IIIB
19	21	F	No	2 years	thyroidectomy	0	IIIB
20	45	F	No	3 years	thyroidectomy	9 g MP	IVB
21	60	F	No	2 years	ATD	0	IVB

at least 6 months before surgery, and medical orbit decompression failed. Orbit irradiation was not performed before surgery in any of the patients. Orbit computer tomography was performed in all patients before surgery, for evaluating the volume and distribution of orbital fat tissue and the volume of extraorbital

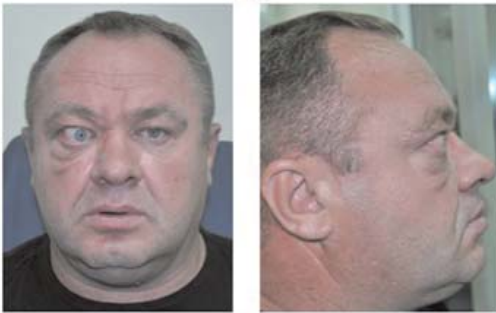muscles, but also for excluding maxillary/ethmoidal sinusitis, or an orbital tumor.

Our series included a single case of emergency intervention, performed to a patient with right malignant proptosis and loss of visual acuity at the right eye (Fig. 1). Surgery was initiated in the chronic phase of ophthalmopathy in all the other



a

Figure 1. Emergency intervention in a patient with right malignant ophthalmopathy and zero visual acuity in the acute phase (patient 15 from Table 1). a. The patient before surgery.



b

b. The same patient 1 year after removal of the inferior and intern orbital walls and extraconal fat in the affected eye.



c. The same patient 4 months after removal of the external orbit wall and more extraconal fat.

cases. The main reasons for surgery were aesthetic (proptosis in 15 cases - e.g. Fig. 2), or aesthetic and functional (diplopia for the other 6 cases, e.g. Fig. 3). When proptosis was the main

addressing cause, inclusion criteria was a measurement greater than 22 mm with Hertel's exophthalmometer before surgery (Table 2).

Table 2. Level of exophthalmos from 24 operated orbits of the 12 patients operated for bilateral exophthalmos

Exophthalmos measured with Hertel's exophthalmometer	Number of operated orbits
22mm-25mm	10
25 mm-28 mm	12
> 28 mm	2

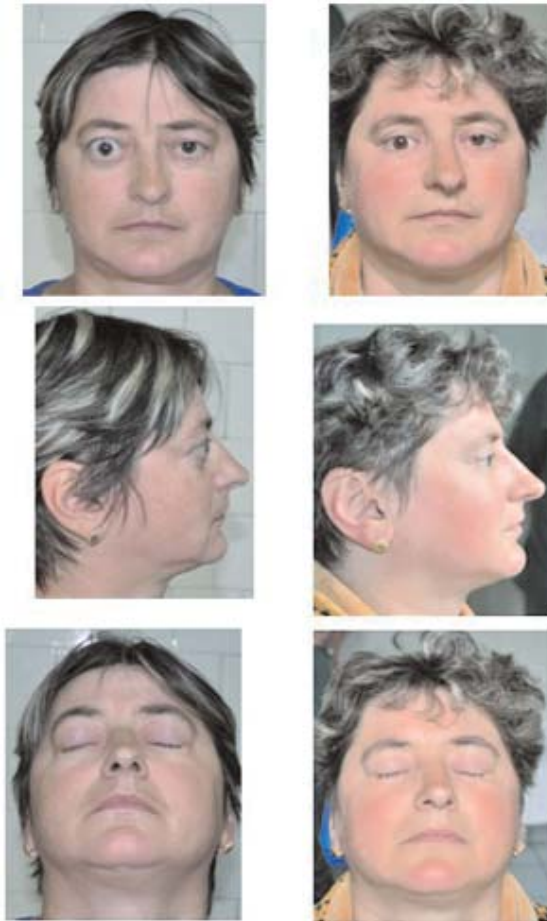

Figure 2. Patient thyroidectomised for Graves' disease and thyroid papillary carcinoma (patient 8 in Table 1) having bilateral exophthalmos in the stable chronic phase, accompanied by mild diplopia and palpebral incompetence (left panel).

Patient was submitted to bilateral surgical decompression, consisting in the removal of extraconal fat tissue through inferior and superior transpalpebral intervention, together with the removal of the orbit floor.

One year after surgery, the patient had diminished bilateral exophthalmos, with the disappearance of diplopia and of palpebral incompetence (right panel).

## RESULTS

We used an inferior and superior transpalpebral approach for most of the cases, by removing the floor of the orbit, followed by lipectomy (removal of both intraconal and extraconal fat in 7 cases, whereas only extraconal fat was removed in the rest of the cases). In 7 cases the access to the orbit floor was made through the inferior rim of the orbit that was temporarily removed. This approach allowed the entire release of the infraorbital nerve from its

osseous channel and to minimize the neurological sequelae. Transconjunctival approach was used in only 5 patients (9 orbits). The internal 2/3 of the orbit floor was removed together with the internal orbit wall using the Morax technique, followed by intraconal and extraconal lipectomy.

Preoperative orbit CT allowed accurate planning of surgical intervention. The presence of large quantities of fat tissue allowed avoiding the removal of more than one orbit wall in many cases of important proptosis.

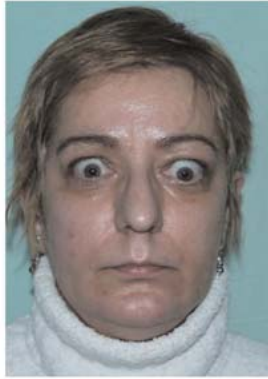
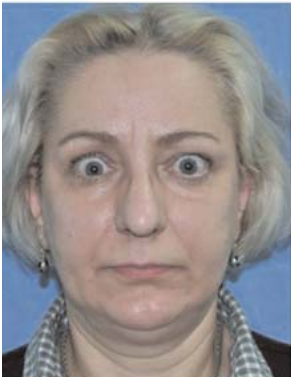
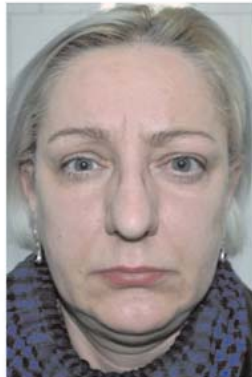Figure 3. Patient with Graves' ophthalmopathy (patient 20 in Table 1) consisting in diplopia with restriction of eye movements and bilateral superior eyelid retraction (a). Therapy consisted in bilateral orbit decompression through removal of the orbit floor and superior and inferior transpalpebral removal of extraconal fat. Two years after surgery, diplopia disappeared and the intervention scars became almost invisible, but a certain degree of superior eyelid retraction persisted (b).

a

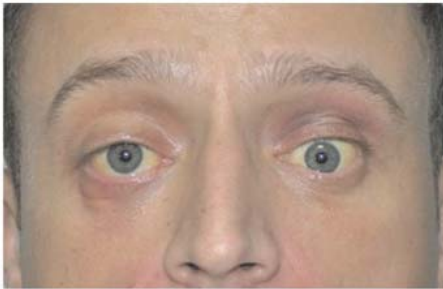

b

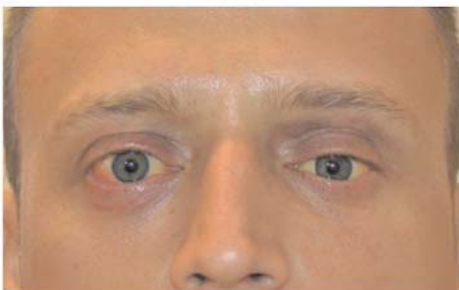

c

The injection of botulinic toxin in the superior eyelid levator completely normalised superior eyelid positions one week after injection (c).



before



after

Figure 4. Patient with bilateral Graves' ophthalmopathy (patient 18 in Table 1) and shortening of the right inferior eyelid 16 months after decompression surgery (upper image), submitted to eyelid lengthening with hard palate mucosal graft (lower image).

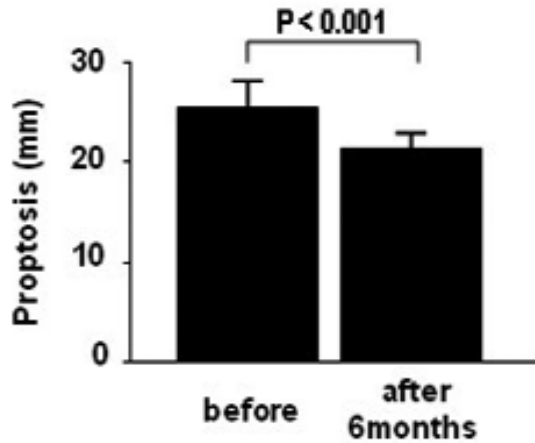


Figure 5. Mean proptosis evaluated by Hertel's exophthalmometry before (left) and after (right) surgery at the 15 patients operated mainly for proptosis reduction.

The volume of removed fat tissue, including intrachanal fat, varied between 0.1 - 2.9 mL from the superior compartments and between 0.5 - 2.8 mL from the inferior compartments. Intrachanal fat removal using the Olivari technique also increased visual acuity in certain cases. This benefit was obvious in the case of unilateral malignant ophthalmopathy, where visual acuity obtained in the right eye after surgery was comparable with the unaffected acuity of the left eye.

Twenty patients were submitted to bilateral eye surgery, lipectomy being sufficient in only one of the two eyes of one case (Fig. 2). Surgical revision was only needed in the patient with malignant orbitopathy at the severely affected side, in order to remove the external orbital wall and more extraconal fat (Fig. 1). Unilateral decompression through fat tissue removal alone was performed in only one patient with unilateral ophthalmopathy.

Mean proptosis was evaluated

before surgery with the Hertel exophthalmometer and compared with measurements obtained 6 months after surgery, using t Student test. Difference was considered significant at P values smaller than 0.05. Proptosis evaluated by Hertel's exophthalmometry was decreased with at least 1 mm in all patients. The most important reduction (with 4.2±1.7 mm, from 25.4±2.7 mm to 21.3±1.6 mm 6 months after surgery) was obtained at the 15 patients operated mainly for proptosis reduction ( $p < 0.001$ , Fig. 5).

We have not performed surgery for strabismus until present. Shortening of the superior eyelid was treated in 7 patients by injections with botulinum toxin in the levator muscle (only one affected side in all cases) (Fig. 3). Another patient needed lengthening of the inferior eyelid with a palatal mucosal graft (Fig. 4).

None of our patients suffered from postoperative new onset, but most patients without initial diplopia described transient diplopia in the first

postoperative week; when present before surgery, diplopia improved significantly or even disappeared after decompression (Fig.3). Only one patient suffered from inferior eyelid retraction set 18 months after surgery and it was corrected with palatal mucosal graft (Fig. 4). All patients with the entire floor of the orbit removed were submitted to anaesthesia of the infraorbital nerve territory. Effects of anaesthesia disappeared in less than two months at patients where orbit rebord was temporarily removed. Infraorbital nerve disesthesia disappeared in less than 6 months from the moment of surgical intervention, with two exceptions, when it persisted for longer than 12 months. None of the patients submitted to transconjunctival decompression through removal of the internal orbital wall from the intraorbital nerve suffered from infraorbital nerve anaesthesia.

## DISCUSSION

Although most authors respect therapy principles consensually established by EUGOGO, surgical techniques used for reaching similar final results differ, possibly also due to different experience and specialization of surgeons involved. The surgery of orbitopathy is made mainly in the sequellar stage (12), preferably after at least 6 months of orbital inactivity (13). The need of emergency surgery is quite rare, referring especially to the rapid decrease of visual acuity through optic neuropathy. When medical treatment and radiotherapy are inefficient, surgical decompression

may help to decrease inflammatory signs, but also those of neuropathy and corneal injury, together with the improvement of diplopia, when present (12).

Surgical orbit decompression has been used since more than 100 years, when Kroenlein described for the first time a technique of lateral orbit wall removal, allowing the enlargement of orbit volume. This technique was initially used for the excision of an intraorbital tumor, being subsequently used as a model for the first orbit decompressions performed by Dolinger in 1890 (14). The indications of surgical decompression were however limited by its related side effects, sequels and morbidity.

The evolution of surgical and anesthetic techniques decreased postoperative risks, therefore indications of surgical orbit decompression were extended from patients with major risk of vision loss to other less threatening pathology (15). Surgical decompression further evolved when Olivari (1991) added the possibility of intra- and extraconal fat resection (16).

The symptomatology of Graves' ophthalmopathy is largely influenced by inefficient venous and lymphatic drainage (17). Improvement of orbit drainage is achievable by simultaneous intervention upon the orbit volume, by increasing it through removal of one or several of its walls, and upon its content, by diminishing it through lipectomy. A combination of these techniques may reduce retrobulbar pressure with at least 8 - 12 mmHg (18).

Another reason for the broadening of indications for orbit decompression is the result inconstancy of noninvasive therapeutic strategies. Glucocorticoid



administration and external radiation were generally proved to be efficient for the therapy of optic nerve neuropathy and orbit inflammation, but less for the improvement of proptosis or diplopia, complications that could be efficiently reversed only by surgical orbit decompression (19, 20).

Graves' orbitopathy could be classified into three types: with prevalence of fat tissue (Type I), with muscle involvement (Type II) and a combination of the two preview types (Type III) (21). The type of orbitopathy is very important in choosing the most suited surgical approach - intervention on the bone walls of the orbit *versus* intervention on fat tissue. The number of orbit walls or the quantity of fat tissue that need to be removed could be decided function of both the type and severity of orbitopathy (22). The reduction of proptosis after surgery could be easily predicted, however, the results of surgery upon diplopia are less predictable (23).

We consider that, besides emergency intervention, there are two other distinct categories of patients with Graves' orbitopathy having indication for orbit surgery: patients with important proptosis, irrespective of the presence of diplopia, and patients where diplopia is the most important complication, but proptosis is non-significant. Other authors (24, 25) consider that orbit inflammation refractory to non-surgical approach may also be an indication for orbit surgery in up to 25% of patients. The psychological impact for choosing orbit surgery is, however, very important in all situations (25, 26). Orbital decompression decreases intraorbital pressure rapidly, together with an improvement of venous and

lymphatic drainage. These modifications cause a decrease of orbitary and periorbital edema, with a decrease of proptosis and exophthalmos and, through a reduction in muscular volume, to the decrease of both diplopia and compression on the optic nerve and subsequent neuropathy.

Both types of intervention - orbit enlargement through intervention on the bone walls or diminished content through lipectomy - have advantages and disadvantages. Our experience suggests that the combination between lipectomy and orbital wall removal adapted to the clinical modifications and radiological features leads to better results, since it allows a more efficient individual adaptation (2, 27, 28). Other authors (21) consider that decompression through intervention on orbit walls only is more efficient on the reduction of the degree of exophthalmos, but it has minimal effects on the correction of diplopia. This type of intervention seems even to be followed by an increased postoperative rate of appearance or aggravation of diplopia, irrespective of the surgical technique - transantral (9) or endoscopic (29). Postoperative evolution of diplopia is however a question of debate, since final results vary greatly from surgical teams using the same surgery technique. For instance, Jernfors (24) decompressed 78 patients through transantral technique (30) and followed them for 15 years, reporting very good and stable results regarding diplopia. None of the patients complained of postoperative-onset diplopia and those who had diplopia before surgery, this complication became less disturbing after surgery, or even completely disappeared. We report

similar results, even if our experience is limited to a fewer number of patients and the follow-up period is shorter. The removal of a large quantity of fat tissue is accompanied by better functional results, but also by mild aesthetical inconvenience (“sunken eyes”) (16).

The development of various surgical refinements, such as the transconjunctival approach, was able to minimize the visible scars. The risk of infraorbital nerve damage can be diminished by the removal of only two thirds of the internal part of the orbit floor and ethmoidal bone (12). This procedure avoids the dissection or contusion of the infraorbital nerve during the removal of the orbit floor, decreasing at the same time the pressure exerted by the orbit content upon the respective nerve due to the disappearance of bone support. Our yet limited experience also showed a postoperatively decreased infraorbital nerve dysfunction with this approach. The decrease of the pressure exerted on the infraorbital nerve could be also reached through a small osteotomy around the infraorbital opening in order to make the nerve loose (31). This type of intervention after approaching the orbit floor through the temporary removal of the orbital rim allows shortening the recovery period of the infraorbital nerve function.

One of the reasons for orbital decompression is increasing the patient comfort. Orbital discomfort is indeed significantly decreased, operated subjects describing a lessening of subjective perception of retro-ocular tension (32). There is no consensus regarding the influence of retroorbital irradiation before surgery upon the results of orbit decompression. Certain authors suggest

that irradiation has no negative effects on the results of surgical therapy for Graves’ ophthalmopathy (33). Irradiation might however have a negative influence upon the results of decompression if the lipectomy procedure is exclusively used (34).

**In conclusion**, surgical therapy for endocrine orbitopathy is efficient, but perfectible regarding all four major aims: orbit decompression, strabism correction, eyelid surgery and aesthetical reasons. The generally predictable results, the reduced rate of complications and the improvement of the quality of life recommend orbit surgery in the chronic phase of Graves’ ophthalmopathy, when exophthalmos or diplopia cause significant discomfort, but also as an emergency procedure, when the risk of vision loss is imminent.

#### **Acknowledgments**

We are grateful to Ms. Gabriela Sylvester for efficient language revision of the paper.

#### **Conflict of interest.**

The authors did not report any conflict of interest.

#### **References**

1. Smith TJ. Pathogenesis of Graves’ orbitopathy: a 2010 update. *J Endocrinol Invest.* 2010; 33(6):414-421.
2. Balmes E, Burcea A, Belgun M, Alexandrescu D, Badiu C. Marine-Lenhart syndrome. Case report and literature review. *Acta Endo-Buc* 2007; 3(2):201-208.
3. Clauser LC, Galiè M, Tieghi R, Carinci F. Endocrine orbitopathy: 11 years retrospective study and review of 102 patients & 196 orbits. *J Craniomaxillofac Surg.* 2012; 40(2):134-141.

4. Borumandi F, Hammer B, Kamer L, von Arx G. How predictable is exophthalmos reduction in Graves' orbitopathy? A review of the literature. *Br J Ophthalmol*. 2011; 95(12):1625-1630.
5. Siracuse-Lee DE, Kazim M. Orbital decompression: current concepts. *Curr Opin Ophthalmol*. 2002; 13(5):310-316.
6. Cozma I, Cozma LS, Boyce RL, Ludgate ME, Lazarus JH, Lane CM. Variation in Thyroid Status in Patients with Graves' Orbitopathy. *Acta Endo-Buc* 2009; 5(2): 191-198.
7. Stiebel-Kalish H, Robenshtok E, Gatton DD. Pathophysiology of Graves' ophthalmopathy. *Pediatr Endocrinol Rev*. 2010; 7 Suppl 2:178-181.
8. Neigel JM, Rootman J, Belkin RI, Nugent RA, Drance SM, Beattie CW, Spinelli JA. Dysthyroid optic neuropathy. The crowded orbital apex syndrome. *Ophthalmology*. 1988; 95(11):1515-1521.
9. Kazim M, Gold KG. A review of surgical techniques to correct upper eyelid retraction associated with thyroid eye disease. *Curr Opin Ophthalmol*. 2011; 22(5):391-393.
10. Sokol JA, Foulks GN, Haider A, Nunery WR. Ocular surface effects of thyroid disease. *Ocul Surf*. 2010; 8(1):29-39.
11. Goh MS, Nab AA. Orbital decompression in Graves' orbitopathy: efficacy and safety. *Internal Med J*. 2005; 35:586-591.
12. Morax S, Badelon I. L'exophtalmie basedowienne. *J. Fr. Ophtalmol*. 2009; 32:589-599.
13. Bartalena L, Baldeschi L, Dickinson A, Eckstein A, Kendall-Taylor P, Marcocci C, Mourits M, Perros P, Boboridis K, Boschi A, Curro N, Daumerie C, Kahaly GJ, Krassas GE, Lane CM, Lazarus JH, Marino M, Nardi M, Neoh C, Orgiazzi J, Pearce S, Pinchera A, Pitz S, Salvi M, Sivelli P, Stahl M, von AG, Wiersinga WM. Consensus statement of the European Group on Graves' orbitopathy (EUGOGO) on management of GO. *Eur J Endocrinol* 2008; 158(3):273-285.
14. Dolinger J. Die Druckentlastung der Augenhöhle durch Entfernung der äußeren Orbitalwand bei hochgradigem Exophthalmos (Morbus Basedowii) und consecutiver Hauterkrankung. *Dtsch Med Wochenschr* 1911; 37:1888-1890.
15. McCord CD. Current trends in orbital decompression. *Ophthalmology* 1985; 92: 2133.
16. Olivari N. Transpalpebral decompression of endocrine ophthalmopathy (Graves' disease) by removal of intraorbital fat: experience with 147 operations over 5 years. *Plast Reconstr Surg*. 1991; 87:627-641.
17. Bartalena L, Wiersinga WM, Pinchera A. Graves' ophthalmopathy: state of the art and perspectives. *J Endocrinol Invest*. 2004; 27:295-301.
18. Otto AJ, Koornneef L, Mourits MP, Deen-Van Leeuwen L. Retrobulbar pressures measured during surgical decompression of the orbit. *Brit J Ophthalmol*. 1996; 80:1042-1045.
19. Bartalena L, Pinchera A, Marcocci C. Management of Graves' Ophthalmopathy: reality and perspectives. *Endocr Rev* 2000; 21:168-199.
20. Mourits MP, van Kempen-Harteveld ML, García MB, Koppeschaar HPF, Tick L, Terwee CB. Radiotherapy for Graves' orbitopathy: randomised placebo-controlled study. *Lancet* 2000; 355:1505-1509.
21. Morax, S., Bok, C., Chahbi, M., and Hurbli, T. Decompression orbitaire au cours de l'exophtalmie dysthyroïdienne. *Ann. Chir. Plast. Esthet*. 1997; 42:207-215.
22. Graham SM, Brown CL, Carter KD, Song A, Nerad JA. Medial and lateral

- orbital wall surgery for balanced decompression in thyroid eye disease. *Laryngoscope* 2003; 113:1206-1209.
23. Stell PM. Transantral orbital decompression in malignant exophthalmos. *J Laringol Otolaryngol*. 2007; 82:613-621.
24. Jernfors M, Välimäki MJ, Setälä K, Malmberg H, Laitinen K, Pitkäranta A. Efficacy and safety of orbital decompression in treatment of thyroid-associated ophthalmopathy: long-term follow-up of 78 patients. *Clin Endocrinol*. 2007; 67:101-107.
25. Zosin I, Balas M, Golu I, Vonica O, Badescu L, Ursoniu S. Diagnostic Approaches in A Series of Cases with Graves' Ophthalmopathy. *Acta Endo-Buch* 2010; 6(4):455-464.
26. Coulter I, Frewin S, Krassas GE, Perros P. Psychological implications of Graves' orbitopathy. *Eur. J Endocrinol*. 2007; 157: 127-131.
27. Bouletreau P, Breton P, Freidel M. Decompression orbitaire au cours des ophtalmopathies basedowiennes. *Rev Stomatol Chir Maxillo-faciale*. 2005; 106:89-93.
28. McCann JD, Goldberg RA, Anderson RL, Burroughs JR, Ben Simon GJ. Medial wall decompression for optic neuropathy but lateral wall decompression with fat removal for non vision-threatening indications. *Am J Ophthalmol*. 2006; 141(5):916-917.
29. Schaefer SD, Solimanzadeh P, Della Rocca DA, Yoo GP, Maher EA, Milite JP, Della Rocca RC. Endoscopic and transconjunctival orbital decompression for thyroid-related orbital apex compression. *Laryngoscope* 2003; 113(3):508-513.
30. Walsh TE, Ogura JM: Transantral orbital decompression for malignant exophthalmos. *Laryngoscope* 1957; 67: 544-568.
31. Clauser LC, Tieghi R. New mini-osteotomy of the infraorbital nerve in bony decompression for endocrine orbitopathy. *J Craniomaxillofac. Surg*. 2010; 21: 222-224.
32. Khan JA, Doane JF, Whitacre MM. Does decompression diminish the discomfort of severe dysthyroid orbitopathy? *Ophthal Plast Reconstr Surg*. 1995; 11:109-112.
33. Baldeschi L, Macandie K, Koetsier E, Blank L, Wiersinga W. The Influence of Previous Orbital Irradiation on the Outcome of Rehabilitative Decompression Surgery in Graves' Orbitopathy. *Am J Ophthalmol*. 2008; 145: 534-540.
34. Richter DF, Stoff A, Olivari N. Transpalpebral decompression of endocrine ophthalmopathy by intraorbital fat removal (Olivari technique): experience and progression after more than 3000 operations over 20 years. *Plast Reconstr Surg*. 2007; 120:109-123.
35. Bartalena L, Baldeschi L, Dickinson A, Eckstein A, Kendall-Taylor P, Marcocci C, Mourits M, Perros P, Boboridis K, Boschi A, Currò N, Daumerie C, Kahaly GJ, Krassas GE, Lane CM, Lazarus JH, Marinò M, Nardi M, Neoh C, Orgiazzi J, Pearce S, Pinchera A, Pitz S, Salvi M, Sivelli P, Stahl M, von Arx G, Wiersinga WM; European Group on Graves' Orbitopathy (EUGOGO). Consensus statement of the European Group on Graves' orbitopathy (EUGOGO) on management of GO. *Eur J Endocrinol*. 2008; 158: 273 - 385.